



Case Report

An Ovarian Dermoid Cyst in Pregnancy: A Rare Cause of Intrauterine Growth Restriction

Das Rubby^{1*}, Rajbhandari Subrina²

¹Department of Gynecology and Obstetrics, Universal College of Medical Sciences, Bhairahawa, Nepal.

²Department of Gynecology and Obstetrics, Universal College of Medical Sciences, Bhairahawa, Nepal.

Date of Submission: March 05, 2020

Received in Revised Form: April 15, 2020

Date of Acceptance: April 28, 2020

Date of Publishing: July 30, 2020

ABSTRACT

The most common ovarian tumour presenting during pregnancy are dermoid cysts, usually present in the second trimester. Mostly dermoid cysts are diagnosed during ultrasound in antenatal period. We report a case of large unilateral dermoid cyst which was missed in all USG done in antenatal period but diagnosed intra-operatively while performing caesarean section for Intra uterine growth restriction (IUGR) with fetal distress. Ovarian cystectomy was done and remaining ovarian tissues were preserved. The large dermoid cyst hampered the proper growth of the fetus in utero leading to IUGR and fetal distress. Ovarian dermoid cyst in antenatal period, a rare cause of IUGR and its successful management prompted us to report this case.

Keywords: Dermoid cyst, Intrauterine Growth Restriction (IUGR), Pregnancy.

***Corresponding Author:** Dr. Rubby Das, Department of Gynecology and obstetrics, Universal College of Medical Sciences, Bhairahawa, Nepal. Mob No: 9843017225, Email: rubbydas@gmail.com.

INTRODUCTION

Ovarian tumours are not common during pregnancy. They are present in 0.3% of pregnancies and usually between 16 - 20 weeks of gestation.¹ The most frequent benign tumors diagnosed during pregnancy, are dermoid cyst and cystadenoma.² Dermoid cysts originate from totipotent germ cells that differentiate abnormally, developing characteristics of mature dermal cells. The gold standard to determine an ovarian tumor during pregnancy is ultrasound.³ With routine ultrasonography during the first trimester, the discovery of an ovarian cyst has become relatively common in the beginning of pregnancy. Its management depends upon the size, symptoms and the duration of pregnancy.

When an adnexal mass is noted incidentally on ultrasound, the majority of small, simple cysts do not pose a risk to the pregnancy and regress spontaneously.³ Very few cases have been reported connecting the cause of IUGR with the size of Ovarian cyst. Qublan et al. reported mucinous cystadenoma of 6300 gm at 38 weeks of pregnancy with IUGR and malpresentation.⁴ Large size may affect the fetal growth, mal-presentation, obstructed labour, rupture of the cyst in addition to wrongful calculation of gestational age and so also increased maternal morbidity due to over distension of abdomen.⁵

CASE HISTORY

A 27-year-old primigravida was referred for further management at 40 weeks and 6 days of gestation with diagnosis of IUGR and not in labour. The patient perceived adequate fetal movement. The gestational age based on her first scan (15 weeks USG) was 39 weeks and 1 day. On admission, her BP was 130/70 mm Hg, pulse 88 b/min regular, respiratory rate 18/min. Her general condition was fair without any signs of pallor, icterus, cyanosis, edema or dehydration. On systemic examination, per abdomen, uterus was 32 weeks size with Symphysis fundal height of 32cm with longitudinal lie, cephalic presentation, fetal parts were palpable and fetal heart rate was 136 beats/min. On speculum examination, cervix was healthy with no evidence of vaginal bleeding or leakage. On vaginal examination, the cervical os was closed, soft posterior, early effaced without show.

She was admitted and investigations sent. Her hemoglobin was 10.3gm%, blood

group A positive, HIV & HbsAg were non-reactive and Glucose Challenge test was 102 mg%. Ultrasound showed a single live fetus corresponding to 33 weeks and 6 days of gestation in cephalic presentation. There were no gross structural abnormalities. Placenta was located on the posterior wall of upper segment with grade II maturity with AFI of 6.5 cm. The estimated fetal weight was 2100 gms. The Cardiotocography revealed late decelerations. Thus, the patient was immediately prepared for Emergency Caesarean Section with the diagnosis of Primigravida at 40 weeks and 6 days of gestation with IUGR with fetal distress.

Under spinal anesthesia, abdomen was opened by a lower transverse incision. A female baby of 1.9 kg was delivered with APGAR score of 8/10 and 9/10 on 1 & 5 min respectively. The baby was low birth weight and had features of IUGR. Intraoperatively, placenta was fundoposterior with grade I meconium stained liquor. Right ovary and both fallopian tubes were normal but left ovary had large cyst of approx. 9×5 cm, round in shape, encapsulated and smooth margin. Capsule was enucleated and cystectomy done. No spillage from the removed cysts happened during surgery. Also, normal ovarian tissues were preserved as much as possible. On cut section, no septations were present and the content was hair with cheesy material. The specimen was sent for histopathological examination. There were no intra-operative or post-operative complications. The baby required NICU care for 48 hours. The patient was discharged on 5th post-operative day along with the baby.

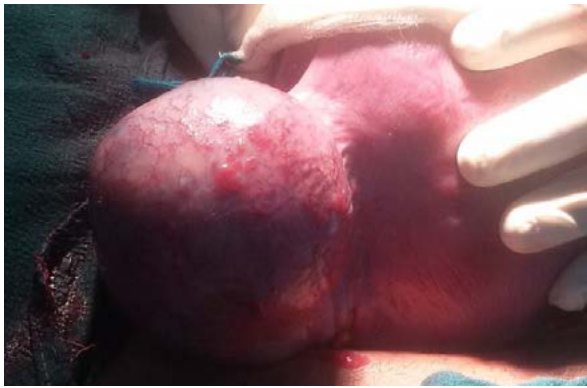


Fig 1: Gross appearance of left ovarian dermoid cyst

Histopathological report revealed ovarian cystic structure measuring 11.5×5.5 cm containing thick cheesy secretion, hair and solid component. The cystic wall was fibro-collagenous and consist of lobules of many sebaceous gland and congested blood vessels, nerve twigs, apocrine glands, lymphatics, hair shafts along with few chronic inflammatory cell infiltrate and macrophages. No immature components/atypia were seen thus confirming the diagnosis of mature cystic teratoma.

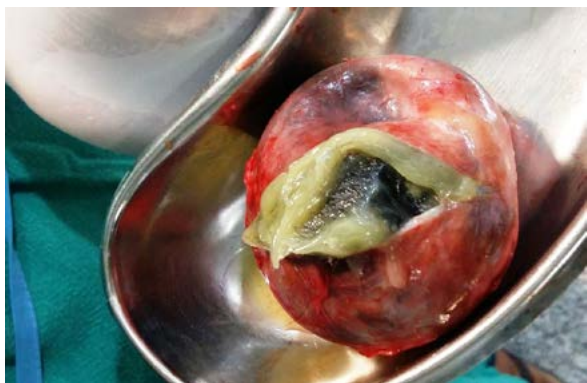

Fig 2: Cut section of dermoid cyst showing cheesy material & hair

DISCUSSION

Dermoid cyst arises from the germ cells arrested after the first meiotic division. It constitutes about 20–40% of all ovarian tumors in pregnancy.⁶ It has low malignant potential and rarely grows larger than a melon,

is unilocular or has very few locules.⁷ Its capsule is thick, smooth and greyish-yellow in colour.⁶ The lining epithelium is typically stratified squamous and contains the usual cutaneous elements like sebaceous glands, hair follicles and sometimes teeth.⁷ Dermoid cyst may remain asymptomatic during pregnancy, and if symptomatic usually has symptoms in the second trimester.⁸ The gold standard to detect an ovarian tumor during pregnancy is ultrasound². A mature cystic teratoma can be diagnosed at ultrasonography by diffusely or partially echogenic mass with the echogenic area owing to sebaceous material and hair within the cavity and also with CT scan or MRI.⁸ During pregnancy, tumor markers are not reliable to assess the risk of malignancy of ovarian masses.²

Any adnexal mass smaller than 5 cm in size during pregnancy rarely causes symptoms.⁹ Symptomatic, solid, bilateral, and complex lesions should be subjected to surgery whenever discovered.⁹ Unilateral simple ovarian cysts, 5-8 cm in size, should be evaluated sonologically up to 16-18 weeks and if they fail to regress or if they increase in size, surgical intervention should be undertaken by 18 wks.⁹ Laparoscopy is possible during the first and second trimester to manage symptomatic presumed benign ovarian tumors.⁵ The risk of miscarriage, following surgery for ovarian tumor during pregnancy is estimated 2.8%.⁴ In our case this large dermoid cyst was diagnosed incidentally during caesarean section done for IUGR with fetal distress. Surprisingly this cyst was not identified in any of the USG, done during the antenatal check-up. Clinically, the baby had features of asymmetric IUGR and required NICU care for 2 days. This may be due to the tumor deriving its blood supply prominently from ovarian vessels or due to compressive effect of the tumor on the uterine blood supply which has also been explained in the case reported by Dipak

Mandi et al.⁹ Several cases of huge ovarian mass with features of fetal growth restriction have been reported in the literature.^{9,10} The complications of adnexal cyst are torsion, hemorrhage, rupture, degeneration, infection or malignant transformations.⁷ All ovarian cysts during pregnancy should be followed up by ultrasonography due to possibility of adverse effects of the cysts on pregnancy.

CONCLUSION

The management of dermoid cysts during pregnancy includes observation if the size of cyst is <5cm or surgery (laprotomy or laproscopic cystectomy). The removal of ovarian benign dermoid cysts intact, by laparotomy during the second trimester of pregnancy can prevent complications of cysts and adverse pregnancy outcome. IUGR in the fetus has emerged as a grave and serious complication thus any ovarian mass in pregnancy should be better evaluated through both clinical and systematic ultrasound, during antenatal period and intrapartum, even in low-resource countries.

ACKNOWLEDGEMENTS

None

REFERENCES

1. Attia L, Chachia A, Ben T R, Bennour G, Makhlof T, Koubaa A. Benign ovarian tumors during pregnancy. A review of 26 cases. *Tunis Med.* 2008;86(7):680–4. [PubMed: 19472731].
2. Tariel O, Huissoud C, Rudigoz RC, Dubernard G. Presumed benign ovarian tumors during pregnancy. *J Gynecol Obstet Biol Reprod.* 2013;42(8):842–55. doi:10.1016/j.jgyn.2013.09.038. [PubMed: 24210242].
3. Sanam M. Surgical Management of an Ovarian Bilateral Multiple Dermoid Cyst During Pregnancy: A Case Report Study. *Middle East J Rehabil Health.* 2016; 3(2):e36097. doi: 10.17795/mejrh-36097
4. Qublan HS, Al-Ghoweri AS, Al-Kaisi NS, AbuKhait SA. Benign mucinous cystadenoma with stromal luteinization during pregnancy: a hormonally responsive tumor and a rare cause of fetal intrauterine growth restriction. *J Obstet Gynaecol Res* 2002 28:104-7. doi: 10.1046/j.1341-8076.2002.00020.x
5. Basant MH, Rukmini K R, Prabhakar G C B. Giant Ovarian Cyst in Term Pregnancy - A rare case report. *Bali Medical Journal.* 2015; 4(1):5-7. P-ISSN.2089 -1180, E-ISSN.2302-2914.
6. Dutta. D C. Benign Lesions of the Ovary. DC DUTTA's TEXTBOOK OF GYNECOLOGY including Contraception. Sixth Edition. New Delhi, Jaypee Brothers Medical Publishers 2014 Chapter 20. P- 293 -294.
7. Malhotra N, Malhotra J, Saxena R, Tumors of Ovary. *Jeffcoate's Principles of Gynaecology.* Eighth Edition. New Delhi, Jaypee Brothers Medical Publishers 2014. Chapter 33. P-504-506; 516-517.
8. Chaudhary H, Jindal A, Sharma P. Ruptured Dermoid Cyst during Pregnancy: A Rare Case Report. *J Gynecol Women's Health.* 2018;10(2):555781. DOI: 10.19080/JGWH.2018.10.555781.
9. Mandi D, Mondal R C, Bhar D. Successful Vaginal Delivery despite a Huge Ovarian Mucinous Cystadenoma Complicating Pregnancy: A Case Report, *IJMS.* 2013; 38(4):113-115.
10. Yenicesu GI, Cetin M, Arici S. A huge ovarian mucinous cystadenoma complicating pregnancy: a case report. *Cumhuriyet Medical Journal.* 2009; 31:174-7.

Cite this article as: Das R, Raj Bhandari S. An ovarian dermoid cyst in pregnancy: a rare cause of Intrauterine growth restriction. *Medphoenix,* 2020;5(1): 75-78